

Indiana University School of Medicine Interlibrary Loan

Docline: INUIND, OCLC: IUM

**ILLiad TN: 759680**



**ILL Number: 33932547**



**Borrower: ILUILL**

**Lending String:**

**Patron:** Curtis, Luke - TN: 347245

**Journal Title:** Seminars in respiratory  
and critical care medicine

**Volume:** 32 **Issue:** 6

**Month/Year:** 2011 **Pages:** 754-63.

doi: 10.1055/s-0031-12

**ISSN:** 1069-3424



**UI:** 22167403



**Article Author:** Thompson G

**Article Title:** Pulmonary  
coccidioidomycosis.

**Print Date:** 12/21/2012 10:04:11 AM

**In Process date:**

**Need by:**

**Call #:**

**Location:**

**Odyssey**

**Charge**

**Maxcost: \$20.00**

**EFTS: No**

**Shipping Address:**

Library of the Health Sciences  
University of Illinois at Chicago  
1750 W. Polk St. M/C 763  
Chicago, IL 60612-7223

**Fax:** 1.312.996-1899

**Ariel:** 128.248.46.209

**Email:** lib-lhsill@uic.edu

**Notes:** ILLINET, GMR-RL, CIC;  
ODYSSEY:206.107.43.25

SHIPPED DEC 21 2012

09

# Pulmonary Coccidioidomycosis

George R. Thompson, III, M.D.<sup>1,2</sup>

## ABSTRACT

Coccidioidomycosis refers to the spectrum of disease caused by the dimorphic fungi *Coccidioides immitis* and *Coccidioides posadasii*. Clinical manifestations vary depending upon both the extent of infection and the immune status of the host. Coccidioidomycosis has been reported to involve almost all organ systems; however, pulmonary disease is the most common clinical manifestation. The incidence of coccidioidomycosis continues to rise, and primary coccidioidal pneumonia accounts for 17 to 29% of all cases of community-acquired pneumonia in endemic regions. The majority of patients with coccidioidomycosis resolve their initial infection without sequelae; however, several patients develop complications of disease ranging in severity from complicated pulmonary coccidioidomycosis to widely disseminated disease with immediately life-threatening manifestations. This review focuses on complications of pulmonary coccidioidomycosis with an emphasis on the management of primary coccidioidal infection, solitary pulmonary nodules, pleural effusions, cavitary disease, acute respiratory distress syndrome (ARDS), miliary disease, and sepsis.

**KEYWORDS:** Coccidioidomycosis, pulmonary, triazoles, amphotericin

Coccidioidomycosis refers to the spectrum of disease caused by the dimorphic fungi *Coccidioides immitis* and *Coccidioides posadasii*. Clinical manifestations vary depending upon both the extent of infection and the immune status of the host. Pulmonary infection is the most common clinical manifestation, although the spectrum of disease ranges from asymptomatic exposure with subsequent immunity against future infection to severe and life-threatening disseminated disease.

## MYCOLOGY AND ETIOLOGIC AGENT(S)

Coccidioidomycosis was first described by a medical student in Argentina in 1892 following the pathological examination of biopsy specimens.<sup>1</sup> Skin biopsy samples revealed organisms similar to the protozoan *Coccidia*, and several years later the organism was thus

named *Coccidioides* ("resembling *Coccidia*") *immitis* ("not mild").

More recent studies have further divided this pathogen into two distinct species, *Coccidioides immitis*, and *Coccidioides posadasii*. It was initially believed that *C. immitis* isolates existed solely in California, whereas *C. posadasii* was responsible for the majority of disease elsewhere. However, it is now known that considerable overlap exists in the geographic distribution of these species, and the clinical manifestations caused by these species are indistinguishable.

## ECOLOGY/EPIDEMIOLOGY

*Coccidioides* spp. are soil-dwelling fungi that exist solely in the semiarid to arid life zones of the southwestern United States, Mexico, and parts of central and South

<sup>1</sup>Department of Internal Medicine, Division of Infectious Diseases, University of California–Davis, Davis, California; <sup>2</sup>Department of Medical Microbiology and Immunology, University of California–Davis, Davis, California.

Address for correspondence and reprint requests: George R. Thompson, III, M.D., Department of Internal Medicine, Division of Infectious Diseases, University of California–Davis, 1 Shields Ave., Tupper Hall, Rm. 3146, Davis, CA 95616 (e-mail:

grthompson@ucdavis.edu).

Pulmonary Fungal Infections; Guest Editors, John W. Baddley, M.D. and Peter G. Pappas, M.D.

Semin Respir Crit Care Med 2011;32:754–763. Copyright © 2011 by Thieme Medical Publishers, Inc., 333 Seventh Avenue, New York, NY 10001, USA. Tel: +1(212) 584-4662.

DOI: <http://dx.doi.org/10.1055/s-0031-1295723>.

ISSN 1069-3424.

America. Several areas of the United States are considered "hyperendemic," including Bakersfield, California, and both Phoenix and Tucson, Arizona. A relationship between climatic conditions and the incidence of coccidioidomycosis has been well documented. Typically moist soil conditions are required for the hyphal form to grow in soil. Following a subsequent dry period, hyphal death occurs leaving viable arthroconidia (spores). Spores are then dispersed through either natural phenomena or human/animal disturbance of the soil.<sup>2</sup>

The incidence of infection with *Coccidioides* spp. has increased in recent years, likely due to population growth and accompanying construction within the southwestern United States.<sup>3,4</sup> Individuals whose occupations involve frequent aerosolization of soil, such as construction and agricultural workers, archaeologists, and excavators are at particularly high risk for contracting coccidioidomycosis.<sup>5-7</sup> Additionally, the increasing number of immunosuppressed patients encountered in clinical practice due to the use of corticosteroids and other immune-modulating drugs,<sup>8</sup> the increasing number of solid organ and bone marrow transplantation,<sup>9,10</sup> and the epidemic of infection with the human immunodeficiency virus (HIV)<sup>11</sup> has also contributed to the rising incidence of coccidioidal infection.

Other groups such as pregnant women in the third trimester are known to be at risk for severe coccidioidomycosis,<sup>12</sup> and an ethnic predisposition to severe infection has been long recognized. Although African American and Filipino patients suffer a disproportionate burden of extrapulmonary disease with a 10- to 175-fold higher risk than other ethnicities, the immunogenetic mechanisms responsible for these differences have yet to be fully elucidated.<sup>12</sup>

Residence or travel to an endemic area is required for infection with *Coccidioides* spp., and even brief exposure may cause symptomatic disease.<sup>13</sup> Human and veterinary cases have been reported outside the recognized endemic regions illustrating the importance

of obtaining a detailed travel history and the potential role of fomites in the investigation of disease exposure.<sup>14</sup>

### Epidemics

Outbreaks of coccidioidomycosis frequently follow natural events such as earthquakes, dust storms, and droughts. The largest recorded outbreaks occurred following a dust storm within the San Joaquin Valley in 1977<sup>15</sup>; the Northridge, California, earthquake of 1994<sup>16</sup>; and a period of prolonged drought within Arizona in 1998-2001.<sup>17</sup>

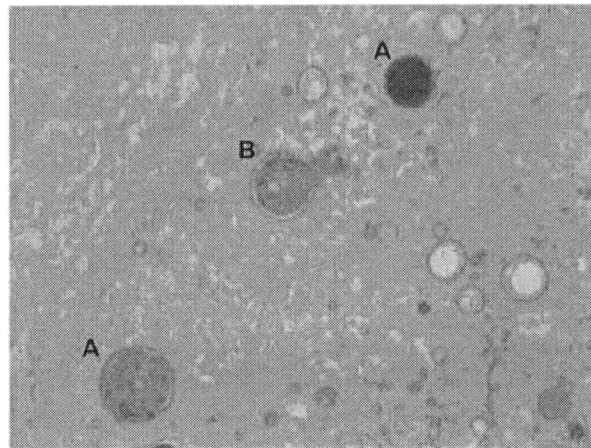
### Bioweapon Potential

The inhalational nature of infection and potential for severe symptoms lasting months has prompted the U.S. government to identify *Coccidioides* spp. as potential agents of bioterrorism. A BSL-3 agent, *Coccidioides* spp. should only be handled by experienced personnel in an appropriate laboratory, and strict regulations govern laboratory investigation of this agent.

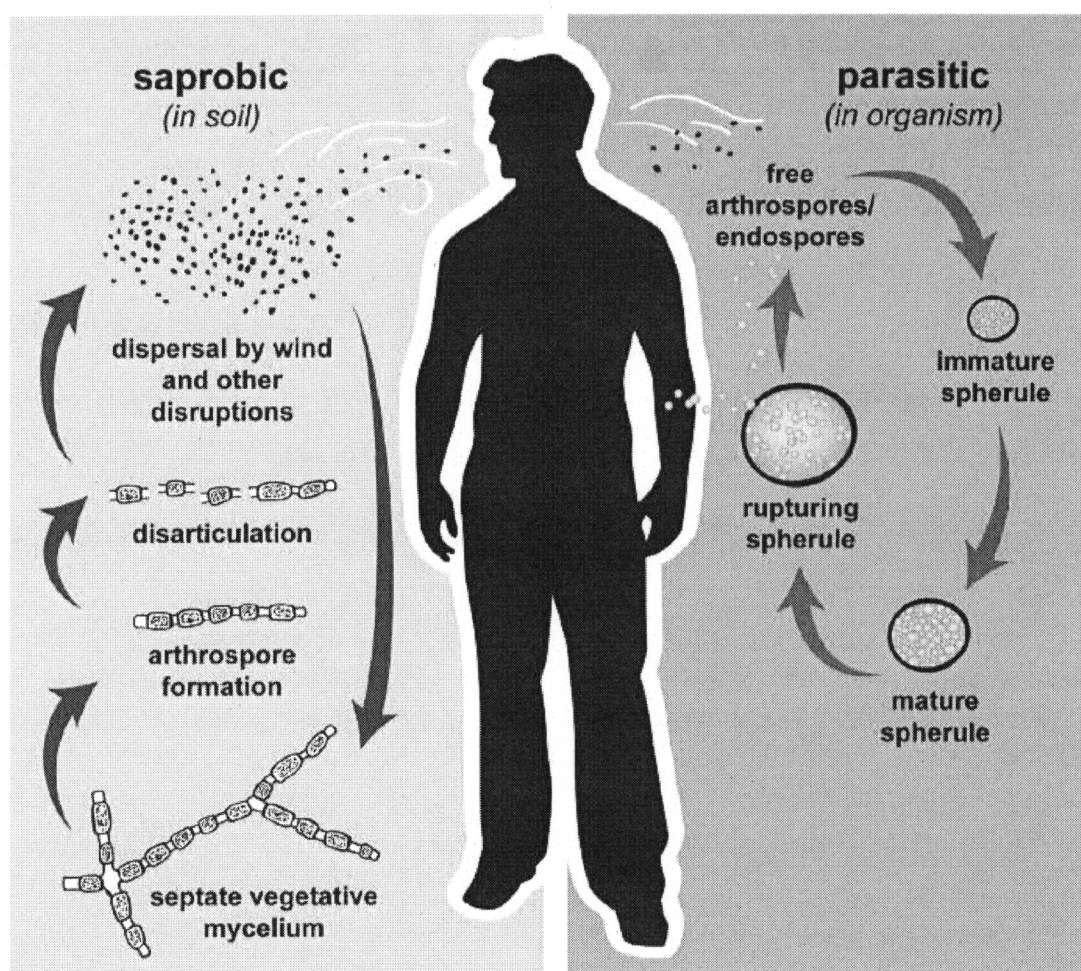
While the theoretic potential for bioterrorism is undisputed, actual use seems unlikely. No method of preparing spores for large-scale aerosolization/spray is known, fewer than 30% of those exposed develop symptoms, and in these patients symptoms are typically delayed several weeks after exposure. In addition, person-to-person transmission does not exist, and fatalities are uncommon and typically occur only after prolonged infection.<sup>18</sup>

### PATHOGENESIS

Following inhalation, arthroconidia are ingested by pulmonary macrophages. Arthroconidia then convert to a round cell that enlarges over the next 3 to 4 days to become a spherule measuring 8 to 30  $\mu\text{m}$  in diameter that contains hundreds of asexual endospores (Fig. 1). Mature spherules ultimately rupture, and endospores



**Figure 1** (A) *Coccidioides* spherules. (B) Endosporulating spherule.



**Figure 2** Life cycle of coccidioidomycosis.

enlarge becoming endosporulating spherules propagating the spherule-endospore cycle (Fig. 2). Endospores may disseminate via hematogenous or lymphatic drainage, and, in the absence of cell-mediated immunity, severe disease may develop.

## CLINICAL MANIFESTATIONS

### Primary Infection

Although several clinical manifestations may present after exposure, more than half of all infections are thought to be subclinical. Apparent illness is most commonly a subacute process known as valley fever (primary coccidioidal infection). Respiratory symptoms such as cough, fever, chills, and fatigue are common and may last weeks to months. In endemic regions primary coccidioidal pneumonia may account for 17 to 29% of all community-acquired pneumonia.<sup>3,19</sup> The development of erythema nodosum accompanying acute illness is usually a favorable prognostic sign. An exanthem mimicking erythema multiforme has also been reported in patients with primary pulmonary infection and, simi-

larly, indicates a favorable immunologic response to coccidioidal infection.<sup>20,21</sup>

Radiographic findings are consistent with segmental or lobar pneumonia, with concomitant mediastinal or hilar lymphadenopathy also commonly observed. Historical reports linked mediastinal lymphadenopathy with increased risk for the development of disseminated disease, but more recent evidence has failed to demonstrate such an association.<sup>22</sup>

The decision to treat primary pulmonary coccidioidomycosis is often individualized as prospective randomized trials have yet to be performed. Some practitioners elect to treat all symptomatic patients, whereas others treat only those with risk factors for complicated infection (HIV/AIDS, organ transplant, third trimester of pregnancy, and those receiving immunosuppressive medications).

Current guidelines favor treatment in patients with symptoms for more than 8 weeks, weight loss of more than 10%, night sweats for more than 3 weeks, infiltrates involving more than one half of one lung or portions of both lungs, prominent or persistent hilar adenopathy, complement fixation antibody titers to *C.*



*immitis* of >1:16, or symptoms that persist for >2 months. The greater risk for disseminated coccidioidomycosis among black and Filipino patients often prompts treatment in these groups as well. Fluconazole and itraconazole are the most commonly prescribed antifungal agents for primary infection, and treatment for 3 to 6 months with frequent clinical, serologic, and radiographic assessment should be prescribed.<sup>23</sup>

## Pulmonary Complications of Coccidioidomycosis

### PLEURAL EFFUSION

Pleural effusions have been estimated to occur in 5 to 15% of primary pulmonary coccidioidomycosis.<sup>21,24</sup> Cough, pleuritic chest pain, and dyspnea are the most common complaints in patients with coccidioidal pleural effusions. The size of effusion varies greatly between patients and does not appear to correlate with risk of disseminated disease. Indeed in a recent series, pleural effusions were diagnosed more often in those with primary pulmonary infection than those with disseminated disease ( $p < 0.001$ ).<sup>24</sup>

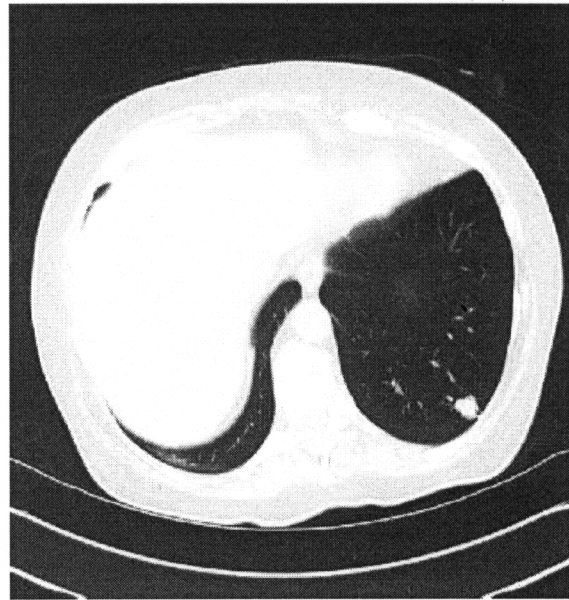Lymphocytes and eosinophils are the predominant cell types found on pleural fluid analysis. The pH, protein, lactate dehydrogenase (LDH), and glucose may vary widely between patients; thus both transudates and exudates can be seen in coccidioidal pleural effusions. Most effusions respond to oral triazole therapy alone without drainage; however, up to 22% of effusions meet criteria for the diagnosis of an empyema and therefore require thoracotomy and antifungal treatment.

### Residual Pulmonary Nodule (Coccidioidoma)

Pulmonary infiltrates in some patients with primary coccidioidal pneumonia will not completely resolve. These lesions are most commonly solitary pulmonary nodules in the peripheral lung parenchyma (Fig. 3). Although typically benign and of little clinical consequence, it is often difficult to differentiate a coccidioidoma from pulmonary malignancy. For this reason, it is recommended that all coccidioidal pulmonary infiltrates be followed to resolution. The majority of patients with residual coccidioidal pulmonary nodules do not maintain a positive complement fixation serological response. However, in many such patients, more sensitive serological tests remain positive. Aspiration, bronchoscopy, or surgical resection is frequently required for definitive diagnosis, and antifungal treatment is not necessary after resection.

### COCCIDIOIDAL CAVITIES

Following primary coccidioidal pneumonia thin-walled cavities may also develop. Two mechanisms have been proposed in an attempt to explain the development of



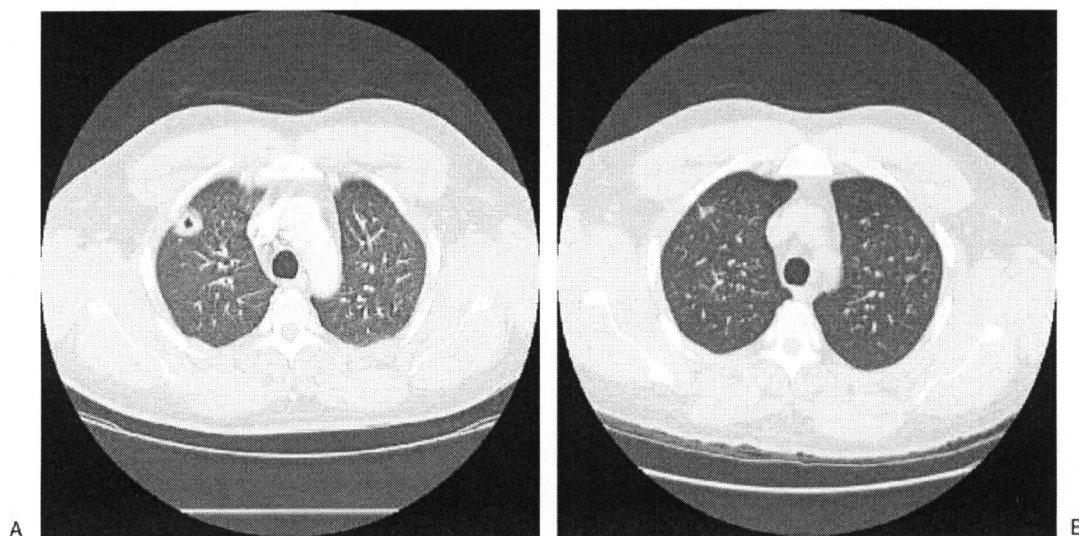
**Figure 3** Residual nodule caused by coccidioidomycosis.

cavitary lesions. One theory proposes that an area of infarction during initial infection or liquefaction of a pulmonary nodule leads to the formation of thin-walled cavities. Alternatively a “ballooning” mechanism surrounding the site of initial infection has been proposed. Antifungal treatment is usually unnecessary in the management of cavitary lesions unless they abut the pleura and threaten bronchopleural fistula formation. In these circumstances surgical intervention is usually recommended. Serial radiographic imaging is often used to follow small cavities over time (Fig. 4).

Ruptured cavities may produce bronchopleural fistulae that present with dyspnea and pleuritic chest pain, and unfortunately fistula formation may be the initial manifestation of coccidioidal infection. A pneumothorax with an accompanying air-fluid level is the hallmark of bronchopleural fistula formation on radiographic imaging. Resection of the ruptured cavity or lobectomy with decortication may be required, although some patients can be managed with antifungal therapy and chest drainage alone.

Chronic fibrocavitary pneumonia (Fig. 5) is more frequent in diabetic patients for reasons that remain unclear. Involvement of more than one lobe of the lung, and a chronic pneumonia characterized by both infiltrates and cavities may also be seen. In addition to the typical pulmonary symptoms of chronic pneumonia, systemic symptoms such as fever, chills, night sweats, and weight loss are frequent.

Cavitary disease may additionally be complicated by the development of a fungus ball caused by either *Aspergillus* spp., in rare cases by *Coccidioides* (Fig. 6), or by bacterial superinfection with subsequent abscess formation.



**Figure 4** (A) Cavitary lung disease. (B) Resolved with antifungal therapy after 12 months.

### Acute Respiratory Failure

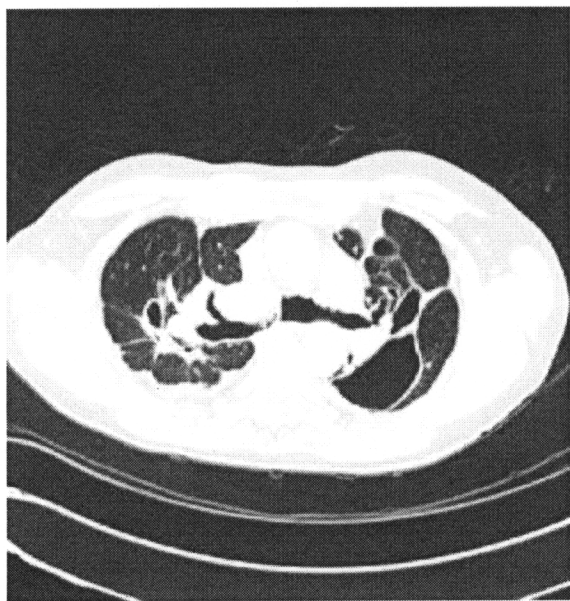Coccidioidomycosis presenting as acute respiratory failure is relatively uncommon. Although rare cases following chronic infection have been reported, acute respiratory failure is traditionally seen in patients with significant underlying immunologic deficits such as those with HIV/acquired immunodeficiency syndrome (AIDS), those receiving immunosuppressive therapy, or those with massive exposure to *Coccidioides* spp. such as archaeologists or construction workers.<sup>25</sup>

### Miliary Disease

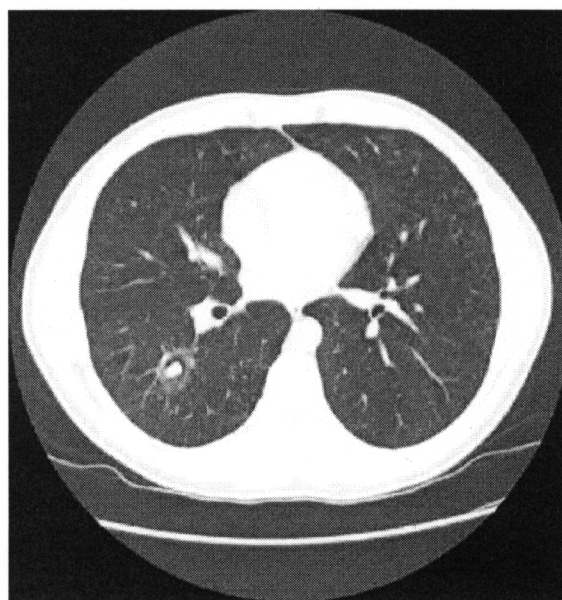
Miliary coccidioidomycosis suggests hematogenous or lymphatic spread of *Coccidioides* spp. and is characterized

by the development of multiple small granulomas throughout the lungs and other organs. Chest x-ray findings show small, millet-seed-sized nodules throughout the lung parenchyma and are indistinguishable from miliary tuberculosis, necessitating expedited diagnostic attempts. This radiographic finding is an ominous sign, with a majority developing the acute respiratory distress syndrome (ARDS),<sup>26</sup> and therefore mandates aggressive antifungal treatment upon presentation if coccidioidomycosis is a diagnostic consideration.

Miliary disease may also represent underlying fungemia with *Coccidioides* spp.<sup>27</sup> Fungemia is most common in those with AIDS, and the highest mortality rates are observed in those with profound CD4+ lymphocyte depletion. In the largest series of coccidioidal



**Figure 5** Chronic fibrocavitary coccidioidomycosis with pneumatocele formation.



**Figure 6** Coccidioidal fungus ball.

fungemia 22/33 patients died during their initial admission, with a mean survival less than 2 weeks from initial presentation.<sup>28</sup> Sepsis due to endemic fungi is uncommon, and even *Coccidioides* spp., the most pathogenic of all endemic mycoses, rarely presents in this fashion.<sup>29,30</sup>

### Acute Respiratory Distress Syndrome

Acute respiratory distress syndrome (ARDS) as a consequence of coccidioidal infection carries nearly a 100% mortality rate. Several meta-analyses and reviews offer conflicting recommendations regarding corticosteroid treatment for ARDS in other populations<sup>31</sup> and this decision is particularly difficult in the setting of proven or possible invasive fungal infections. Limited data are available to guide the clinician, though case reports and case series have failed to demonstrate deleterious effects of corticosteroids in the treatment of coccidioidomycosis-associated ARDS.<sup>32</sup> Some have advocated for systemic steroids tapering over 21 days in the treatment of coccidioidomycosis-associated ARDS. This proposed protocol is similar to that used during treatment of severe *Pneumocystis* pneumonia (prednisone 40 mg twice daily for 5 days followed by 40 mg daily for 5 days, followed by 20 mg daily for 11 days). For those unable to tolerate oral corticosteroid administration, intravenous methylprednisolone may be substituted for oral prednisone at 75% percent of the prednisone dose.

### DIAGNOSIS

A history of potential exposure to *Coccidioides* spp. is essential, and travel or residence to an endemic area may be suggestive of the diagnosis. However, rare cases in nonendemic regions have been attributed to organ donors with unrecognized coccidioidomycosis<sup>33</sup> and fomites containing soil from endemic regions.<sup>34</sup> The protean manifestations of disease may make the diagnosis difficult; however, the presence of eosinophilia suggests the diagnosis in some patients.

Criteria establishing proven and probable coccidioidomycosis have been previously established (Table 1).<sup>35</sup> Proven disease is documented in a host with an illness consistent with *Coccidioides* spp. and one of the following: (1) recovery in culture from a specimen obtained from the affected site or from blood; (2) histopathological or direct microscopic demonstration of the agent (such as *Coccidioides* species spherules); (3) demonstration of coccidioidal antibody in cerebrospinal fluid (CSF), or a two-dilution rise measured in two consecutive blood samples tested concurrently in the setting of an ongoing infectious process. Probable disease is established in a clinical picture consistent with coccidioidomycosis and mycological evidence, such as a positive serological result.

**Table 1 Criteria for the Diagnosis of Endemic Mycoses**

#### Diagnosis and Criteria

##### Proven endemic mycosis

In a host with an illness consistent with an endemic mycosis, one of the following:

Recovery in culture from a specimen obtained from the affected site or from blood.

Histopathological or direct microscopic demonstration of appropriate morphological forms with a truly distinctive appearance characteristic of dimorphic fungi, such as *Coccidioides* species spherules.

For coccidioidomycosis, demonstration of coccidioidal antibody in cerebrospinal fluid, or a two-dilution rise measured in two consecutive blood samples tested concurrently in the setting of an ongoing infectious disease process.

##### Probable endemic mycosis

Presence of a host factor, plus a clinical picture consistent with endemic mycosis and mycological evidence, such as a positive *Histoplasma* antigen test result from urine, blood, or cerebrospinal fluid.

### Culture

*Coccidioides* spp. do not require special media and can be recovered from sputum and skin lesions, and, in rare cases, may be found on blood cultures. Identifiable as a downy, grayish-white colony with a tan to brown reverse, cultures represent a severe biohazard to exposed laboratory personnel. All cultures with hyphal growth should be handled in appropriate biosafety cabinets. Definitive identification is possible through the use of a commercially available molecular probe (Gen-Probe Inc., San Diego, CA)<sup>36</sup> and obviates the need for more labor intensive testing such as animal inoculation.

### Histopathology

Endosporulating spherules, "empty" ruptured spherules, and immature nonendosporulating spherules are the most common pathological findings observed in coccidioidomycosis. Spherules are large (20 to 80  $\mu$ m) and, although visible with hematoxylin and eosin staining, are best observed with the use of periodic acid-Schiff (PAS) or Gomori methenamine silver (GMS) stains. Mycelia are infrequently found in tissue and are indistinguishable from other molds by microscopic characteristics alone.

### Immunologic Methods

Diagnostic challenges in obtaining biopsy specimens and concerns regarding exposure to laboratory personnel have engendered great interest in serological diagnostic techniques. Although latex agglutination assays and

enzyme-linked immunoassays are commercially available both of these methods have a significant number of false-positive reactions, thereby limiting their utility.<sup>37,38</sup> False-positive results are common in the examination of CSF or diluted serum samples by these methods.<sup>39</sup>

The use of immunodiffusion and complement fixation testing remains the most specific method for the diagnosis of coccidioidomycosis. The detection of coccidioidal precipitin [immunoglobulin M (IgM)] or complement fixing (IgG) antibody by immunodiffusion testing is followed by complement fixation testing to provide a quantitative result. This result is indicative of illness severity, has been correlated with the risk of disseminated disease, and is useful in monitoring the response to antifungal therapy in afflicted patients.<sup>40</sup>

### Antigen Detection

In rare cases, patients with coccidioidomycosis have been noted to exhibit false-positive *Histoplasma* urine antigen testing. Following this observation, a coccidioidal urinary antigen test was developed exhibiting a sensitivity of 71%.<sup>41</sup> Antigen detection may be useful in selected cases of coccidioidal infection such as early in the course of infection prior to the development of antibodies or in immunocompromised patients who are unable to manifest a humoral response.

### Polymerase Chain Reaction

Polymerase chain reaction (PCR) testing has been pursued in an attempt to enable diagnostic testing on sputum or to increase sensitivity in immunocompromised patients.<sup>42,43</sup> However, in clinical practice results have been disappointing due to limited sensitivity (44 to 56%).<sup>43</sup>

## TREATMENT—SELECTION OF ANTIFUNGAL AGENTS

### Azoles

The introduction of the azoles was a significant breakthrough in the treatment of coccidioidomycosis and enables clinicians and patients to avoid prolonged courses of amphotericin B formulations. Ketoconazole was the first agent in this class to be used in the treatment of coccidioidomycosis, although only 20 to 30% of patients demonstrated a clinical response to 200 to 400 mg/d.<sup>44</sup> Dose escalation was attempted in the hopes of increasing drug efficacy<sup>45</sup>; however, gastrointestinal intolerance, adrenal insufficiency, and gynecomastia ultimately limited the use of this agent.<sup>46</sup>

Fluconazole has excellent bioavailability and tissue penetration and few drug–drug interactions, and it is typically well tolerated even at high doses. These attrib-

utes have allowed fluconazole to become the agent of choice in cases of nonskeletal coccidioidal infection, and efficacy has been demonstrated in randomized, controlled trials.<sup>47</sup> Favorable pharmacokinetic/pharmacodynamic (PK/PD) parameters and the response rates seen in prior reports<sup>48,49</sup> have prompted current guidelines to recommend fluconazole (800 to 1000 mg/d) as the preferred agent for meningeal infection.<sup>23</sup>

Itraconazole has excellent in vitro activity against *Coccidioides* spp., and multiple well designed prospective trials have confirmed its efficacy in chronic and extrapulmonary infection.<sup>50</sup> Itraconazole is the preferred agent for skeletal lesions and has demonstrated a greater response rate than fluconazole in a blinded comparison.<sup>47</sup> A capsular form and solution are both currently available. Itraconazole solution has greater bioavailability than capsules and is maximally absorbed in the fasting state.<sup>51</sup> If the capsule form is preferred, a high-fat meal with an acidic beverage is recommended to maximize absorption.

Voriconazole has excellent in vitro activity against *Coccidioides* spp.; however, few clinical data are currently available.<sup>52,53</sup> Similar to fluconazole, voriconazole is an attractive choice due to favorable pharmacokinetics/pharmacodynamics even in the CSF. However, drug costs, lack of prospective trials, and need for therapeutic drug monitoring have relegated this agent to the salvage setting.

Posaconazole is currently available only in a liquid formulation and should be taken with a fatty meal and acidic beverage. Several open-label studies have evaluated the potential efficacy of posaconazole in chronic refractory coccidioidomycosis with favorable results.<sup>54–56</sup>

Isavuconazole, ravuconazole, and albaconazole are in variable stages of clinical development, and further clinical data are needed to define their role in the treatment of coccidioidomycosis.

### Echinocandins

The echinocandins including caspofungin, micafungin, and anidulafungin have little inherent activity against *Coccidioides* spp. in the mycelial phase; however, potential efficacy has been demonstrated in murine models of infection.<sup>57</sup> Publications describing the potential efficacy of these agents are limited to case reports<sup>58,59</sup> and at this time should not be used as monotherapy in the treatment of coccidioidomycosis.

### Amphotericin B

Amphotericin B formulations are now reserved almost entirely for those with refractory disease or those with severe manifestations of infection. Although little data has been published regarding the efficacy of amphotericin B formulations in the treatment of coccidioidal

meningitis, animal studies suggest the potential superiority of lipid amphotericin B formulations over fluconazole.<sup>60,61</sup>

### Interferon Gamma

In vitro studies have demonstrated that interferon gamma (IFN- $\gamma$ ) production by peripheral blood mononuclear cells is reduced in patients with chronic coccidioidomycosis,<sup>62,63</sup> and defects within the interleukin-12 (IL-12)/IFN- $\gamma$  have been reported in several patients with disseminated coccidioidal infection.<sup>64,65</sup> These findings have increased interest in providing exogenous IFN- $\gamma$  to augment the antifungal effects of effector cells (macrophages and neutrophils), and successful adjunctive use in the salvage setting has been reported.<sup>66</sup>

### Pregnancy Considerations

As previously discussed, pregnant patients, particularly within the third trimester, are at increased risk for the development of severe coccidioidomycosis.<sup>12</sup> Triazoles are teratogenic and contraindicated during pregnancy; therefore, amphotericin B formulations are used until the child can be safely delivered.

### PROPHYLAXIS

Prophylaxis is limited to individuals following laboratory exposure to high inocula<sup>67</sup> and to selected transplant patients receiving organs from donors with known seropositivity or proven coccidioidal infection.<sup>68</sup>

### FUTURE DIRECTIONS

Despite the expanding antifungal armamentarium currently available antifungals fail to fully eradicate infection in patients with chronic coccidioidomycosis. Nikkomycin Z has shown promise in murine models of infection<sup>69</sup> and may be a welcome addition to the available agents for coccidioidal infection. The recognition that recovery from naturally acquired infection leads to resistance against future infection has prompted an interest in vaccine studies; however, these trials are several years away. Further research is urgently needed in an attempt to improve outcomes in patients with complicated coccidioidomycosis.

### REFERENCES

1. Hirschmann JV. The early history of coccidioidomycosis: 1892–1945. *Clin Infect Dis* 2007;44(9):1202–1207
2. Kolivras KN, Comrie AC. Modeling valley fever (coccidioidomycosis) incidence on the basis of climate conditions. *Int J Biometeorol* 2003;47(2):87–101

3. Sunenshine RH, Anderson S, Erhart L, et al. Public health surveillance for coccidioidomycosis in Arizona. *Ann N Y Acad Sci* 2007;1111:96–102
4. Centers for Disease Control and Prevention (CDC). Increase in Coccidioidomycosis-California, 2000–2007. *MMWR Morb Mortal Wkly Rep* 2009;58(5):105–109
5. Werner SB, Pappagianis D, Heindl I, Mickel A. An epidemic of coccidioidomycosis among archeology students in northern California. *N Engl J Med* 1972;286(10):507–512
6. From the Centers for Disease Control and Prevention. Coccidioidomycosis in workers at an archeologic site—Dinosaur National Monument, Utah, June–July 2001. *JAMA* 2001;286(24):3072–3073
7. Petersen LR, Marshall SL, Barton-Dickson C, et al. Coccidioidomycosis among workers at an archeological site, northeastern Utah. *Emerg Infect Dis* 2004;10(4):637–642
8. Bergstrom L, Yocum DE, Ampel NM, et al. Increased risk of coccidioidomycosis in patients treated with tumor necrosis factor alpha antagonists. *Arthritis Rheum* 2004;50(6):1959–1966
9. Blair JE, Logan JL. Coccidioidomycosis in solid organ transplantation. *Clin Infect Dis* 2001;33(9):1536–1544
10. Glenn TJ, Blair JE, Adams RH. Coccidioidomycosis in hematopoietic stem cell transplant recipients. *Med Mycol* 2005;43(8):705–710
11. Masannat FY, Ampel NM. Coccidioidomycosis in patients with HIV-1 infection in the era of potent antiretroviral therapy. *Clin Infect Dis* 2010;50(1):1–7
12. Rosenstein NE, Emery KW, Werner SB, et al. Risk factors for severe pulmonary and disseminated coccidioidomycosis: Kern County, California, 1995–1996. *Clin Infect Dis* 2001;32(5):708–715
13. Cairns L, Blythe D, Kao A, et al. Outbreak of coccidioidomycosis in Washington state residents returning from Mexico. *Clin Infect Dis* 2000;30(1):61–64
14. Lan F, Tong YZ, Huang H, Xiong WN, Xu YJ, Xiong SD. Primary pulmonary coccidioidomycosis in China. *Respirology* 2010;15(4):722–725
15. Flynn NM, Hoepfich PD, Kawachi MM, et al. An unusual outbreak of windborne coccidioidomycosis. *N Engl J Med* 1979;301(7):358–361
16. Schneider E, Hajjeh RA, Spiegel RA, et al. A coccidioidomycosis outbreak following the Northridge, Calif, earthquake. *JAMA* 1997;277(11):904–908
17. Park BJ, Sigel K, Vaz V, et al. An epidemic of coccidioidomycosis in Arizona associated with climatic changes, 1998–2001. *J Infect Dis* 2005;191(11):1981–1987
18. Fierer JKT, Kirkland T. Questioning CDC's "select agent" criteria. *Science* 2002;295(5552):43
19. Vugia DJ, Cummings KC, Karon A; Centers for Disease Control and Prevention. Increase in coccidioidomycosis - California, 2000–2007. *MMWR Morb Mortal Wkly Rep* 2009;58(5):105–109
20. DiCaudo DJ, Yiannias JA, Laman SD, Warschaw KE. The exanthem of acute pulmonary coccidioidomycosis: clinical and histopathologic features of 3 cases and review of the literature. *Arch Dermatol* 2006;142(6):744–746
21. Lonky SA, Catanzaro A, Moser KM, Einstein H. Acute coccidioidal pleural effusion. *Am Rev Respir Dis* 1976;114(4):681–688
22. Mayer AP, Panse PF, Ko MG, Files JA, Ruddy BE, Blair JE. Does the presence of mediastinal adenopathy confer a risk for disseminated infection in non-immunocompromised persons with pulmonary coccidioidomycosis? In: Programs and

- Abstracts of the 55th Annual Coccidioidomycosis Study Group Davis, CA; 2011. Oral presentation
23. Galgiani JN, Ampel NM, Catanzaro A, Johnson RH, Stevens DA, Williams PL; Infectious Diseases Society of America. Practice guideline for the treatment of coccidioidomycosis. *Clin Infect Dis* 2000;30(4):658–661
  24. Merchant M, Romero AO, Libke RD, Joseph J. Pleural effusion in hospitalized patients with Coccidioidomycosis. *Respir Med* 2008;102(4):537–540
  25. Larsen RA, Jacobson JA, Morris AH, Benowitz BA. Acute respiratory failure caused by primary pulmonary coccidioidomycosis. Two case reports and a review of the literature. *Am Rev Respir Dis* 1985;131(5):797–799
  26. Arsuru EL, Kilgore WB. Miliary coccidioidomycosis in the immunocompetent. *Chest* 2000;117(2):404–409
  27. Ampel NM, Ryan KJ, Carry PJ, Wieden MA, Schiffman RB. Fungemia due to Coccidioides immitis: an analysis of 16 episodes in 15 patients and a review of the literature. *Medicine (Baltimore)* 1986;65(5):312–321
  28. Rempe S, Sachdev MS, Bhakta R, Pineda-Roman M, Vaz A, Carlson RW. Coccidioides immitis fungemia: clinical features and survival in 33 adult patients. *Heart Lung* 2007;36(1):64–71
  29. Arsuru EL, Bellinghausen PL, Kilgore WB, Abraham JJ, Johnson RH. Septic shock in coccidioidomycosis. *Crit Care Med* 1998;26(1):62–65
  30. Lopez AM, Williams PL, Ampel NM. Acute pulmonary coccidioidomycosis mimicking bacterial pneumonia and septic shock: a report of two cases. *Am J Med* 1993;95(2):236–239
  31. Tang BM, Craig JC, Eslick GD, Seppelt I, McLean AS. Use of corticosteroids in acute lung injury and acute respiratory distress syndrome: a systematic review and meta-analysis. *Crit Care Med* 2009;37(5):1594–1603
  32. Shibli M, Ghassibi J, Hajal R, O'Sullivan M. Adjunctive corticosteroids therapy in acute respiratory distress syndrome owing to disseminated coccidioidomycosis. *Crit Care Med* 2002;30(8):1896–1898
  33. Wright PW, Pappagianis D, Wilson M, et al. Donor-related coccidioidomycosis in organ transplant recipients. *Clin Infect Dis* 2003;37(9):1265–1269
  34. Tang TH, Tsang OT. Images in clinical medicine: fungal infection from sweeping in the wrong place. *N Engl J Med* 2011;364(2):e3
  35. De Pauw B, Walsh TJ, Donnelly JP, et al; European Organization for Research and Treatment of Cancer/Invasive Fungal Infections Cooperative Group; National Institute of Allergy and Infectious Diseases Mycoses Study Group (EORTC/MSG) Consensus Group. Revised definitions of invasive fungal disease from the European Organization for Research and Treatment of Cancer/Invasive Fungal Infections Cooperative Group and the National Institute of Allergy and Infectious Diseases Mycoses Study Group (EORTC/MSG) Consensus Group. *Clin Infect Dis* 2008;46(12):1813–1821
  36. Sandhu GS, Kline BC, Stockman L, Roberts GD. Molecular probes for diagnosis of fungal infections. *J Clin Microbiol* 1995;33(11):2913–2919
  37. Huppert M, Peterson ET, Sun SH, Chitjian PA, Derrevere WJ. Evaluation of a latex particle agglutination test for coccidioidomycosis. *Am J Clin Pathol* 1968;49(1):96–102
  38. Kuberski T, Herrig J, Pappagianis D. False-positive IgM serology in coccidioidomycosis. *J Clin Microbiol* 2010;48(6):2047–2049
  39. Pappagianis D, Krasnow RI, Beall S. False-positive reactions of cerebrospinal fluid and diluted sera with the coccidioid latex-agglutination test. *Am J Clin Pathol* 1976;66(5):916–921
  40. Crum NF, Lederman ER, Stafford CM, Parrish JS, Wallace MR. Coccidioidomycosis: a descriptive survey of a reemerging disease. Clinical characteristics and current controversies. *Medicine (Baltimore)* 2004;83(3):149–175
  41. Durkin M, Connolly P, Kuberski T, et al. Diagnosis of coccidioidomycosis with use of the Coccidioides antigen enzyme immunoassay. *Clin Infect Dis* 2008;47(8):e69–e73
  42. Johnson SM, Simmons KA, Pappagianis D. Amplification of coccidioid DNA in clinical specimens by PCR. *J Clin Microbiol* 2004;42(5):1982–1985
  43. Vucicevic D, Blair JE, Binnicker MJ, et al. The utility of Coccidioides polymerase chain reaction testing in the clinical setting. *Mycopathologia* 2010;170(5):345–351
  44. Galgiani JN, Stevens DA, Graybill JR, Dismukes WE, Cloud GA. Ketoconazole therapy of progressive coccidioidomycosis: comparison of 400- and 800-mg doses and observations at higher doses. *Am J Med* 1988;84(3 Pt 2):603–610
  45. Graybill JR, Craven PC, Donovan W, Matthew EB. Ketoconazole therapy for systemic fungal infections: inadequacy of standard dosage regimens. *Am Rev Respir Dis* 1982;126(1):171–174
  46. Pont A, Graybill JR, Craven PC, et al. High-dose ketoconazole therapy and adrenal and testicular function in humans. *Arch Intern Med* 1984;144(11):2150–2153
  47. Galgiani JN, Catanzaro A, Cloud GA, et al; Mycoses Study Group. Comparison of oral fluconazole and itraconazole for progressive, nonmeningeal coccidioidomycosis: a randomized, double-blind trial. *Ann Intern Med* 2000;133(9):676–686
  48. Galgiani JN, Catanzaro A, Cloud GA, et al; The NIAID-Mycoses Study Group. Fluconazole therapy for coccidioid meningitis. *Ann Intern Med* 1993;119(1):28–35
  49. Johnson RH, Einstein HE. Coccidioid meningitis. *Clin Infect Dis* 2006;42(1):103–107
  50. Graybill JR, Stevens DA, Galgiani JN, Dismukes WE, Cloud GA; NIAID Mycoses Study Group. Itraconazole treatment of coccidioidomycosis. *Am J Med* 1990;89(3):282–290
  51. Barone JA, Moskovitz BL, Guarnieri J, et al. Enhanced bioavailability of itraconazole in hydroxypropyl-beta-cyclodextrin solution versus capsules in healthy volunteers. *Antimicrob Agents Chemother* 1998;42(7):1862–1865
  52. Proia LA, Tenorio AR. Successful use of voriconazole for treatment of Coccidioides meningitis. *Antimicrob Agents Chemother* 2004;48(6):2341
  53. Freifeld A, Proia L, Andes D, et al. Voriconazole use for endemic fungal infections. *Antimicrob Agents Chemother* 2009;53(4):1648–1651
  54. Stevens DA, Rendon A, Gaona-Flores V, et al. Posaconazole therapy for chronic refractory coccidioidomycosis. *Chest* 2007;132(3):952–958
  55. Anstead GM, Corcoran G, Lewis J, Berg D, Graybill JR. Refractory coccidioidomycosis treated with posaconazole. *Clin Infect Dis* 2005;40(12):1770–1776
  56. Catanzaro A, Cloud GA, Stevens DA, et al. Safety, tolerance, and efficacy of posaconazole therapy in patients with nonmeningeal disseminated or chronic pulmonary coccidioidomycosis. *Clin Infect Dis* 2007;45(5):562–568
  57. González GM, Tijerina R, Najvar LK, et al. Correlation between antifungal susceptibilities of Coccidioides immitis in vitro and antifungal treatment with caspofungin in a mouse



- model. *Antimicrob Agents Chemother* 2001;45(6):1854–1859
58. Park DW, Sohn JW, Cheong HJ, et al. Combination therapy of disseminated coccidioidomycosis with caspofungin and fluconazole. *BMC Infect Dis* 2006;6:26
  59. Antony S. Use of the echinocandins (caspofungin) in the treatment of disseminated coccidioidomycosis in a renal transplant recipient. *Clin Infect Dis* 2004;39(6):879–880
  60. Clemons KV, Sobel RA, Williams PL, Pappagianis D, Stevens DA. Efficacy of intravenous liposomal amphotericin B (AmBisome) against coccidioidal meningitis in rabbits. *Antimicrob Agents Chemother* 2002;46(8):2420–2426
  61. Clemons KV, Capilla J, Sobel RA, Martinez M, Tong AJ, Stevens DA. Comparative efficacies of lipid-complexed amphotericin B and liposomal amphotericin B against coccidioidal meningitis in rabbits. *Antimicrob Agents Chemother* 2009;53(5):1858–1862
  62. Ampel NM, Kramer LA. In vitro modulation of cytokine production by lymphocytes in human coccidioidomycosis. *Cell Immunol* 2003;221(2):115–121
  63. Ampel NM, Christian L. In vitro modulation of proliferation and cytokine production by human peripheral blood mononuclear cells from subjects with various forms of coccidioidomycosis. *Infect Immun* 1997;65(11):4483–4487
  64. Vinh DC, Masannat F, Dzioba RB, Galgiani JN, Holland SM. Refractory disseminated coccidioidomycosis and mycobacteriosis in interferon-gamma receptor 1 deficiency. *Clin Infect Dis* 2009;49(6):e62–e65
  65. Vinh DC. Coccidioidal meningitis: disseminated disease in patients without HIV/AIDS. *Medicine (Baltimore)* 2011;90(1):87
  66. Kuberski TT, Servi RJ, Rubin PJ. Successful treatment of a critically ill patient with disseminated coccidioidomycosis, using adjunctive interferon-gamma. *Clin Infect Dis* 2004;38(6):910–912
  67. Stevens DA, Clemons KV, Levine HB, et al. Expert opinion: what to do when there is *Coccidioides* exposure in a laboratory. *Clin Infect Dis* 2009;49(6):919–923
  68. Blair JE, Mulligan DC. Coccidioidomycosis in healthy persons evaluated for liver or kidney donation. *Transpl Infect Dis* 2007;9(1):78–82
  69. Hector RF, Zimmer BL, Pappagianis D. Evaluation of nikkomycins X and Z in murine models of coccidioidomycosis, histoplasmosis, and blastomycosis. *Antimicrob Agents Chemother* 1990;34(4):587–593